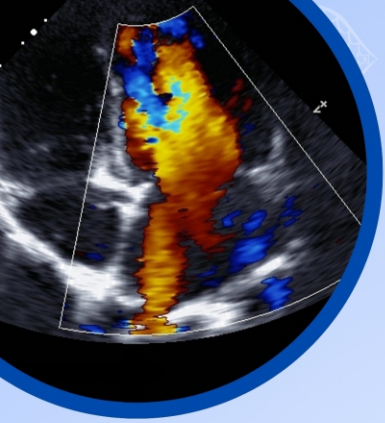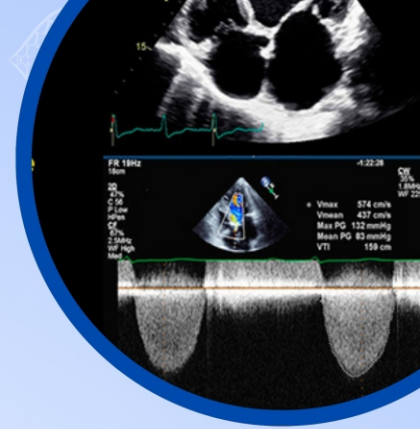


Indian Academy of
ECHOCARDIOGRAPHY



MID TERM CONFERENCE

OF

INDIAN ACADEMY OF ECHOCARDIOGRAPHY

Par excellence teaching cases, debate and clinical discussion
by reputed national & international faculty



Date: 02-Feb 2025



Venue: The Lalit, New Delhi

Organizing Committee

Rakesh Gupta
Executive
Organizing President

S K Parashar **H K Chopra**
National Organizing Presidents

Sameer Shrivastava
Chairman
Organizing Committee

Rajat Mohan
Chairman Coordination Committee

IAE Executive Committee

R Manivasagam
President

Shantanu Sengupta
President Elect

Hansa Gupta
Vice President

Simmi Manocha
General Secretary

Ashok Garg
Joint Secretary

(All Executive Committee Members)



MID TERM IAE CONFERENCE

February 2, 2025, New Delhi

Look at the program, you can not miss it

PROVISIONAL SCIENTIFIC PROGRAM

SAVE YOUR DATE

	Registration
8:30 AM – 8:43 AM	Prologue Welcome: Meeting Objectives Overview:
8:45 AM - 9:30 AM	Opening Batsmen Smashing Cases (6+1min) <ul style="list-style-type: none">● Case 1: TBD● Case 2: Rarest of rare valvular disease● Case 3: Interesting case of right heart failure● Case 4: LV dysfunction with a cyst in heart● Case 5: How MMI saved a life,
9:30 AM - 10:30 AM	INTERINSTITUTIONAL PAR EXCELLENCE CASES (8+2 mins) <ul style="list-style-type: none">● Inflamed Pericardium - A diagnostic minefield● What is the cause of LVOT obstruction● Portal vein as another window to the heart● An uncommon interesting case of valvular heart disease● A case of PH. Unraveling the cause'
10:30 AM - 11:25 AM	EMERGING CONCEPTS & DILEMMAS IN VALVULAR HEART DISEASE (Case based presentation) (10 +2 mins) <ul style="list-style-type: none">● Pathologies of tricuspid valve● Assessing significance & severity of forgotten PR● Does mean diastolic gradient in mitral stenosis has some value in assessing severity in 2025 or should be discarded● NSAA with AR - What is the cause?● TAVI: What is new in 2025
11:25 AM - 11:40 AM	Break
10:40 AM - 12:20 AM	FIVE EYE OPENER CASES (8 mins) <ul style="list-style-type: none">● Two Cases of LAVI Stress Echo● ANCA-associated cardiac disease - case-based presentation● An unusual cause of cardiogenic shock:● A unique case of stroke● Young men with VT

PICK YOUR DATE !! BLOCK YOUR DATE !!

12.20 PM - 12.45 PM	<p>DEBATE Valvular heart disease management: Catheter vs the Knife, which is better? Catheter: No, the knife: Rebuttal: General Consensus:(2 mins)</p>
12:45 PM - 1:15 PM	<p>TEACHING CASES Let us Have Some Fun!</p>
1:15 PM - 1:45 PM	<p>LUNCH</p>
1:45 PM - 2:45 PM	<p>CONGENITAL HEART DISEASE Read with Masters (8+2mins)</p> <ul style="list-style-type: none"> ● Case 1: Broken heart in a child ● Case 2: Calcification of vessels in a foetus ● Case 3: Lord of rings ● Case 4: Scimitar syndrome and it's masquerading ● Case 5: Unusual case of cyanotic HD ● Case 6: TBD
2:45 PM - 3:30 PM	<p>BACK TO BASIC CLINICAL CARDIOLOGY. RECENT ADVANCES IN CARDIOVASCULAR THERAPIES (10 mins)</p> <ul style="list-style-type: none"> ● CKM & HFpEF: Clinico-Echo Therapeutic Navigation ● HFrEF: Which is the main pillar in management ● Semaglutide & Obesity: Where are we today ● Inclisiran; Indications, safety, efficacy & outcome
3:30 PM - 5:15 PM	<p>A MIXED SPECTACULAR SESSION TO REMEMBER</p> <p>SESSION 1. My case of the year (7+2 mins)</p> <ul style="list-style-type: none"> ● Case 1: Double chambered LA / Myocardial tuberculosis ● Case 2: My one imaging failure in five decades, Why? ● Case 3: TBD ● Case 4: What is complete , corrected ,and isolated malposition? <p>SESSION 2: Myocardial work: When & how (8+2 mins)</p> <p>SESSION 3: Any added role of strain imaging vs LVEF in cardio-oncology? What recent literature says (8+2 mins)</p> <p>SESSION 4: Purely case based discussion</p> <p>Unknown cases of diastolic function: Is it normal, abnormal or indeterminate: Solving the dilemma (15 mins)</p> <p>SESSION 5. T-20 Rapid fire cases (7+1 mins)</p> <ul style="list-style-type: none"> ● RV cardiomyopathy or pulmonary embolism ● An interesting case of structural heart intervention (Lampoons procedure), ● Strain Echocardiography for myocardial viability ● Interpret this abnormal Doppler image ● LVH in a case of CKD, What is the cause ?
5:15 PM	<p>ADJOURN</p>

[Click Here to Register Online](#)

